

Features of skin wound healing in rats with experimental chronic kidney disease

S. B. Pavlov* **, O. B. Litvinova* **, N. M. Babenko*

**Kharkiv Medical Academy of Postgraduate Education, Kharkiv, Ukraine*

***H. S. Skovoroda Kharkiv National Pedagogical University, Kharkiv, Ukraine*

Article info

Received 05.09.2021

Received in revised form
02.10.2021

Accepted 03.10.2021

*Kharkiv Medical Academy
of Postgraduate Education,
Amosova st., 58,
Kharkiv, 61176, Ukraine.
Tel.: +38-096-501-77-40.
E-mail: o-b-l@i.ua*

*H. S. Skovoroda Kharkiv
National Pedagogical
University, Faninsky lane,
3-v, Kharkiv,
61166, Ukraine.
Tel.: +38-057-702-15-30.
E-mail:
kaf-anatomy-physiology@
hnpu.edu.ua*

Pavlov, S. B., Litvinova, O. B., & Babenko, N. M. (2021). Features of skin wound healing in rats with experimental chronic kidney disease. Regulatory Mechanisms in Biosystems, 12(4), 594–598. doi:10.15421/022181

Chronic kidney disease negatively affects the morphofunctional state of all organs due to hemodynamic and metabolic disorders. Changes in the content of cytokines observed in kidney diseases, which regulate the processes of inflammation and tissue repair, can complicate the course of the wound process. This research aimed to study disorders in the process of skin wound repair due to changes in the dynamics of production of interleukins IL-1 β , IL-6, IL-10, IL-4, growth factors bFGF and VEGF in animals with experimental chronic kidney disease. The levels of interleukins and growth factors were determined on the 7th, 14th and 28th days after surgical modeling of wounds in the blood of rats with experimental chronic kidney disease and animals of the control group. To assess the dynamics and quality of wound healing, a semi-quantitative histological analysis was performed. The study showed an increase in the content of pro-inflammatory interleukins in the group of sick rats: on the 7th day the level of IL-1 β was 1.19 times higher, and IL-6 – 1.55 times, on the 14th day the level of IL-1 β was 1.37 times in comparison with the control group. The maximum increase in the concentration of anti-inflammatory interleukins was noted on the 28th day: IL-4 was 2.10 times higher, IL-10 – 1.39 times higher than in the control group. The content of bFGF and VEGF in animals of the control group reached its maximum on the 7th day, and in animals with chronic kidney disease – on the 15th day after surgery. Semi-quantitative histological analysis showed a decrease in indicators in the group of sick animals: the number of fibroblasts and collagen deposition – on the 7th day, reepithelialization – on the 28th day. A persistent increase in the number of polymorphonuclear leukocytes was also noted at all periods of the experiment: by 1.38, 1.99, and 9.82 times – on the 7th, 14th, and 28th days, respectively. The study showed that the dynamics of the production of interleukins and growth factors were impaired in rats with chronic kidney disease. In the process of damage regeneration in sick animals, pro-inflammatory mechanisms prevailed with the involvement of a large number of immunocompetent cells, as a result, skin wounds took longer to heal.

Keywords: renal pathology; skin regeneration; chronic wounds; interleukins; basic fibroblast growth factor; vascular endothelial growth factor.

Introduction

The problem of wound healing remains a topical issue in human physiology. Chronic, long-term non-healing skin injuries are often the result of systemic diseases. The negative impact of diabetic disease and chronic venous insufficiency on the processes of soft tissue regeneration is well known (Dissemond, 2017; Wang et al., 2019). Less studied are the processes of wound healing in patients with chronic kidney disease (CKD), which has a fairly high prevalence among the population (10–15%) (Vanholder, 2017; Ammirati, 2019). Hemodynamic and metabolic disturbances, accumulation of uremic toxins, and oxidative stress, which are common in CKD, can negatively affect the healing of skin wounds (Seth et al., 2013; Maroz & Simman, 2014). Skin biopsy studies in patients with all stages of CKD revealed a thinning of the capillary network, microangiopathic changes, including changes in the basement membrane and necrosis of endothelial cells of capillaries, arterioles, and venules, and, as a consequence, poor tissue perfusion (Querfeld et al., 2020). Common cutaneous manifestations of CKD are neuropathies with a decreased density of intraepidermal nerve fibers, nephrogenic systemic fibrosis, calciphylaxis, and systemic amyloidosis (Chao et al., 2011; Robles-Mendez et al., 2015).

The healing process of an acute wound is a sequence of major overlapping healing stages: hemostasis, inflammation, proliferation, and remodeling. The dynamics, quantitative and qualitative characteristics of reparative processes are strictly coordinated and regulated by many factors. Among them, interleukins and growth factors are important. Proin-

flammatory interleukins, for example, IL-1 β and IL-6, begin to be synthesized immediately after injury and promote the activation of leukocytes and their attraction to the wound, stimulate hematopoiesis and the formation of acute-phase proteins (Anders et al., 2016; Hirano, 2021). After cleansing the wound from infectious agents and tissue detritus, anti-inflammatory interleukins such as IL-10 and IL-4 are synthesized; they inhibit the synthesis of proinflammatory cytokines, inhibit the cytotoxic activity of T cells, macrophages, regulate the proliferation and apoptosis of B lymphocytes, fibroblasts, epithelial and endothelial cells (Steen-Louws et al., 2019). Along with interleukins, the basic fibroblast growth factor (bFGF) and vascular endothelial growth factor (VEGF) play an important role in the healing of skin wounds (Tang et al., 2014). Of all the known growth factors, bFGF has the broadest range of target cells. It stimulates the migration and proliferation of fibroblasts, endothelial cells, and keratinocytes increase the rate of formation and growth of granulation tissue, new vessels, epidermal regeneration. Thanks to these properties, bFGF significantly accelerates the regeneration of skin wounds. (Zhu et al., 2017). One of the most important and powerful stimulators of angiogenesis is VEGF. It acts as an endothelial cell mitogen, a chemotactic agent, and an inducer of vascular permeability (Honnegowda et al., 2015).

Against the background of the adverse effects of chronic diseases, including CKD, the dynamics of the production of interleukins and growth factors changes, which can lead to impaired repair of damaged tissues and the formation of long-term non-healing wounds. (Pavlov et al., 2019; Beyene et al., 2020). The majority of patients with CKD are characterized by a chronic inflammatory status, accompanied by a decrease in renal

function with an increase in the systemic inflammatory response (Gupta et al., 2012). Previous studies show an increase in the production of both pro-inflammatory and anti-inflammatory interleukins in kidney disease (Li et al., 2019; Romanova et al., 2020). At the same time, there are impaired reparative processes in the case of damage to the skin and other organs (Maroz & Simman, 2014). Studies of growth factors bFGF and VEGF in CKD show both an increase (Romanova et al., 2020) and a decrease (Stompór et al., 2002) in their content, which often depends on the severity of CKD and the level of systemic inflammation.

The present research aimed to identify disorders in the healing process of skin wounds due to changes in the dynamics of the production of interleukins IL-1 β , IL-6, IL-10, IL-4, growth factors bFGF and VEGF in animals with experimental chronic disease.

Materials and methods

Permission of the Ethics and Bioethics Commission of the Kharkiv Medical Academy of Postgraduate Education dated 11/12/2019 was obtained for the study. The conditions for keeping laboratory animals included a natural light regime, an optimal temperature (20–22 °C), a standard diet, and free access to water (Guide for the care and use of laboratory animals, 2011). Experimental work was carried out in compliance with international requirements for the treatment of animals (Directive 2010/63/EU of the European parliament and of the Council of 22 September 2010 on the Protection of Animals used for Scientific Purposes; European Convention for the Protection of Vertebrate Animals used for Experimental and other Scientific Purposes. ETS No.123, 1986). Surgical interventions in animals were performed under anesthesia with zoletil (tiletamine hydrochloride and zolazepam hydrochloride) intramuscularly (10 mg/kg of animal body weight).

Studies were performed on 48 Wistar rats weighing 220–280 g at the age of 9 months. Animals were divided into two groups: control (n = 24) and experimental (n = 24). The animals of the experimental group were rats with pre-formed CKD, which developed 8 weeks after a single injection

of 50% aqueous glycerol solution at a dose of 10 mL/kg animal body weight (Vlahovic et al., 2007). Intact animals of the control group in a similar way were injected with saline. The development of CKD was controlled by the method (Kondakov et al., 2013). For the study of the functional state of the kidneys from each group, 15 rats were randomly selected for urine samples, and 6 rats for blood samples. Blood for the study was taken from the heart. In urine samples, levels of protein and creatinine were determined, and their daily excretion was calculated. The blood samples were measured for creatinine and urea. The content of analytes was determined using DAK-SpectroMed kits (Moldova). By the clearance of endogenous creatinine, the glomerular filtration rate was calculated. The remaining rats of the control (n = 18) and experimental (n = 18) groups reproduced the chronic wound model in the form of a circle with a diameter of 20 mm in the interscapular region (Zinatullin et al., 2014). On the 7th, 15th, and 28th days after the application of wounds, 6 rats from each group were removed from the experiment (Fig. 1).

The cytokines' content in serum was determined by ELISA using IL-1 β , IL-6, IL-4, IL-10, VEGF (Vector-Best), bFGF (Elabscience) kits.

Standard techniques were used for histological examination of wound samples. The preparations were analyzed with a PrimoStar microscope (Zeiss). A semi-quantitative method was used to evaluate the following histological processes and structures: reepithelization stage, polymorphonuclear leucocytes (PMNL), fibroblasts, new vessels, and new collagen (Gal, et al., 2008). The sections were evaluated blindly, according to the scale: 0, 1, 2, 3, 4 (Table 1).

Statistical processing of the results was performed using Statistica 6.0 (StatSoft Inc., USA) statistical analysis package. To describe the results obtained, the data were presented as $x \pm SE$, where x is the arithmetic mean, SE is the standard error of the arithmetic mean. Differences between the values in the groups were determined using ANOVA, where the differences were considered significant at $P < 0.05$ (taking into account Bonferroni correction). For histograms used in histological and cytokine examinations were plotted by GraphPad Prism 8 software (GraphPad Software, USA).

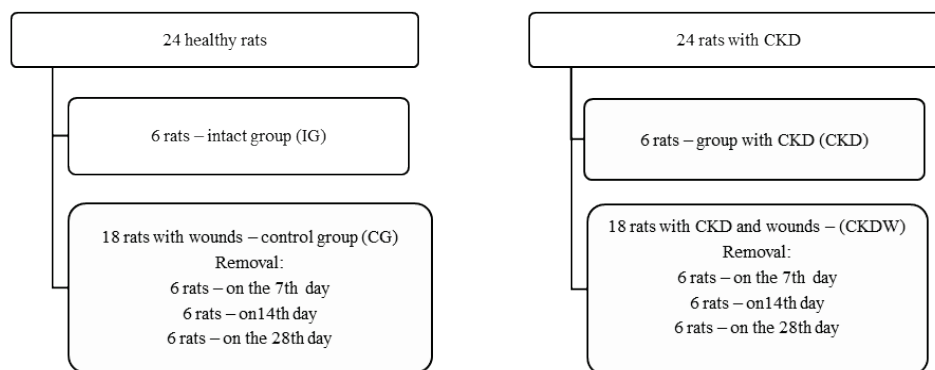


Fig. 1. The scheme of the research

Table 1
Semiquantitative histological evaluation of healing skin wounds

Scale	Reepithelization stage	Polymorphonuclear leukocytes	Fibroblasts	New vessels	Collagen
0	thickening of cut edges	absent	absent	absent	absent-granulation tissue
1	migration of cells (<50%)	mild-surrounding tissue	mild-surrounding tissue	mild-surrounding tissue	minimal-granulation tissue
2	migration of cells (\geq 50%)	mild-granulation tissue	mild-granulation tissue	mild-granulation tissue	mild-granulation tissue
3	bridging the excision	moderate-granulation tissue	moderate-granulation tissue	moderate-granulation tissue	moderate-granulation tissue
4	keratinization	marked-granulation tissue	marked-granulation tissue	marked-granulation tissue	marked-granulation tissue

Results

The study of the levels of proinflammatory cytokines in unoperated rats of the Int and CKD groups showed a significant increase in IL-6 in animals with experimental CKD – 1.89 times ($P < 0.05$). In rats with experimental wounds, the content of proinflammatory interleukins was maximal on the 7th day. At the same time, in the CKDW group, the level of IL-1 β was 1.19 times higher, and IL-6 was 1.55 times higher in comparison with CG ($P < 0.05$). On the 14th day, the concentration of IL-1 β in the blood of animals of the CKDW group exceeded the value in CG by

1.37 times ($P < 0.05$) (Fig. 1). The study of the content of anti-inflammatory cytokines revealed an increase in the level of IL-4 in the CKD group by 2.33 times ($P < 0.05$) in comparison with IG. Among the operated animals, this indicator was the highest in the CKDW group after 28 days and was 2.10 times higher ($P < 0.05$) in comparison with CG. The IL-10 level in the CKDW group was 1.34 times lower on the 7th day, and 1.21 and 1.39 times higher on the 14th and 28th day, respectively ($P < 0.05$ compared with CG, Fig. 2).

The content of growth factors bFGF and VEGF in animals with experimental wounds in CG was maximal on the 7th day, and in CKDW –

on the 15th day after surgery (Fig. 4). According to the semi-quantitative histological analysis in the CKWD group, there was a decrease in indicators: the number of fibroblasts and collagen deposition – on the 7th day, reepithelialization – on the 28th day ($P < 0.05$, in comparison with CG). There was also a persistent increase in the number of polymorphonuclear leukocytes at all periods of the experiment: 1.38, 1.99, and 9.82 times – on the 7th, 14th, and 28th days, respectively ($P < 0.05$, in comparison with CG). At later, in comparison with CG, terms (on the 14th and 28th days), an increase in the number of fibroblasts and newly formed vessels was observed (Fig. 5).

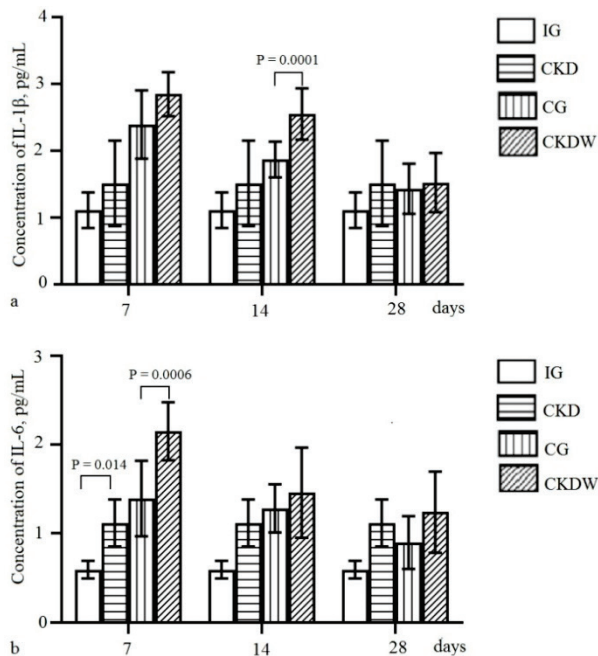


Fig. 2. Content of pro-inflammatory interleukins in the blood of experimental rats on days 7, 14, and 28: *a* – IL-1 β , *b* – IL-6; $x \pm SE$, $n = 6$, using ANOVA ($P < 0.05$) with Bonferroni correction

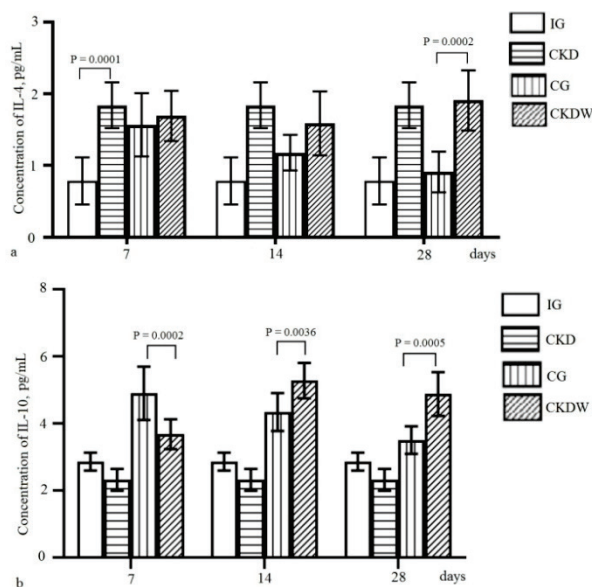


Fig. 3. The content of anti-inflammatory interleukins in the blood of experimental rats on days 7, 14, and 28: *a* – IL-4, *b* – IL-10; $x \pm SE$, $n = 6$, using ANOVA ($P < 0.05$) with Bonferroni correction

Semi-quantitative histological analysis showed the completion of damage regeneration processes at the end of the experiment (28th day) in animals of the control group. During this period in rats of the CKWD group, the healing of skin wounds continued. Signs of a remodeling phase were observed in the form of proliferation of fibroblasts, newly formed vessels, incomplete collagen deposition, and keratinization of the epider-

mis. Focal and diffuse leukocyte infiltration was noted in the areas of histopreparations of wounds in sick animals, which reflected the course of inflammatory processes.

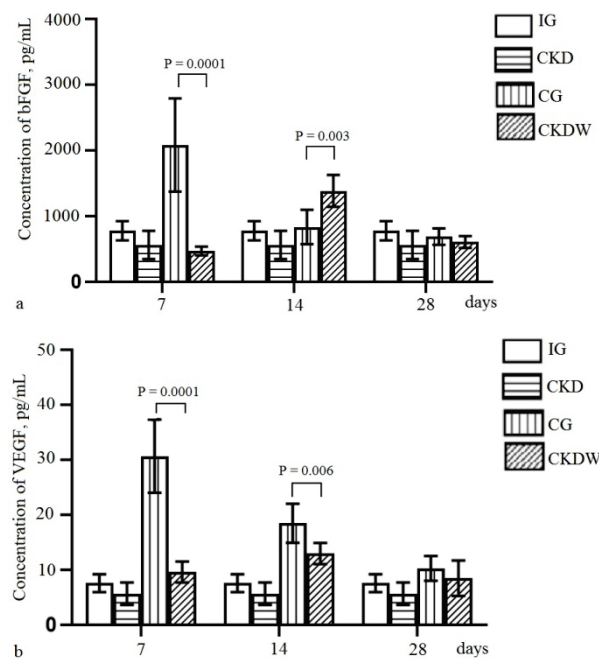


Fig. 4. Content of growth factors in the blood of experimental rats on days 7, 14, and 28: *a* – bFGF, *b* – VEGF; $x \pm SE$, $n = 6$, using ANOVA ($P < 0.05$) with Bonferroni correction

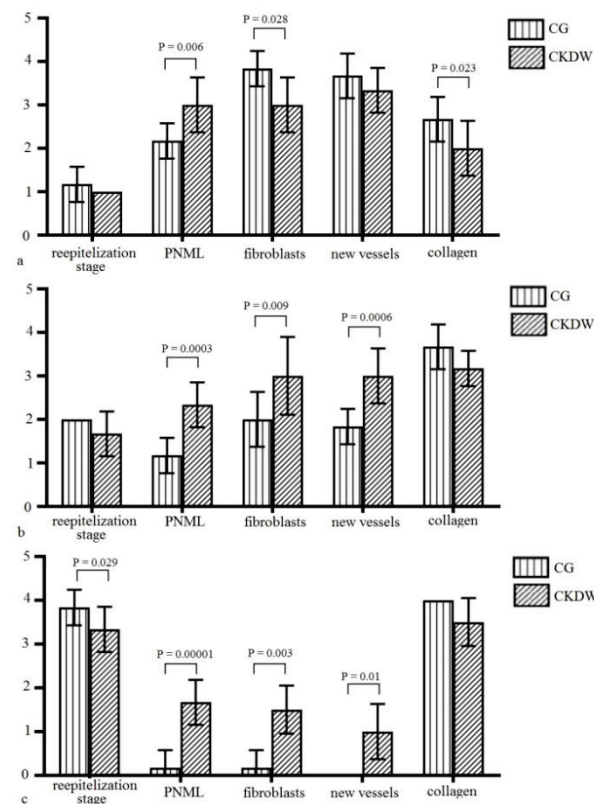


Fig. 5. Semi-quantitative histological analysis data: *a* – on the 7th day, *b* – on the 14th day, *c* – on the 28th day; $x \pm SE$, $n = 6$, using ANOVA ($P < 0.05$) with Bonferroni correction

Discussion

The results of this study indicate signs of dysregulation of reparative processes in animals with experimental CKD. In rats of the CKD and

CKDW groups, increased blood levels of pro-inflammatory interleukins were noted, which is typical for patients with kidney disease and can cause systemic inflammation and multiple organ dysfunction (Petreski et al., 2021). Systemic inflammation is mainly promoted by the production of IL-1 β . The release of IL-1 β initiates the synthesis of acute-phase proteins in the liver, activates endothelial cells, causing fever, mobilizes neutrophils from the bone marrow (leukocytosis), and activates all classes of leukocytes (Anders, 2016). Elevated plasma IL-6 levels are also an unfavourable prognostic factor for the course of CKD and related complications (Barreto et al., 2010). At the same time, a significant increase in the concentration of IL-6 can be considered as a manifestation of compensation, since this interleukin also has anti-inflammatory properties, inhibiting the production of IL-1 β , reducing the recruitment of neutrophils and monocytes (Narazaki & Kishimoto, 2018). The increased production of anti-inflammatory IL-4 and IL-10 is also likely a reflection of compensatory processes. Previous studies have shown that increased production of these interleukins reduces the intensity of inflammation in rats with experimental CKD (Summers et al., 2011; Souza et al., 2018).

In animals with experimental CKD, the concentrations of growth factors were significantly reduced. The dynamics of bFGF and VEGF production during the repair process were also impaired. Their peak plasma concentration in rats of the CKDW group fell on the 14th day after the operation, while in the control – on the 7th day. This is probably a consequence of long-term inflammatory processes in the body of sick animals (Stompór et al., 2002). At the same time, the concentration of bFGF, we believe, reached a sufficient level by the 14th day after surgery, which was reflected at the tissue level in the form of an increase in the number of fibroblasts, newly formed collagen, and blood vessels. In addition to local effects, increasing the concentration of bFGF can also have a beneficial systemic effect. Its ability has been established to indirectly inhibit the expression of proinflammatory cytokines, including IL-6 and IL-1 β , which suppresses inflammation and the associated response to oxidative stress (Sheng et al., 2018). Even though VEGF is a key angiogenic factor and increases during hypoxia accompanying both kidney disease and chronic wounds, its content in the blood of animals of the CKD and CKDW groups was lower than in healthy animals. Some studies show that the inflammatory environment in CKD suppresses VEGF expression, and antiangiogenic factors such as thrombospondin-1 and endostatin are active in kidney disease (Kang et al., 2001; Tanaka et al., 2015). Thus, angiogenesis is impaired at several levels in chronic kidney disease: due to insufficient basic response to hypoxia, due to an increase in antiangiogenic factors, and insufficient recovery mechanisms (Querfeld et al., 2020).

The combination of changes in the production of interleukins and growth factors in rats of the CKDW group caused disturbances in the process of wound healing. We observed pronounced signs of inflammation in histological preparations of wounds of sick animals – leukocyte infiltration at all periods of the experiment was significantly higher than in the control group. The rates of reepithelialization and formation of granulation tissue slowed down: the number of newly formed vessels, fibroblasts, and collagen produced by them on the 14th and 28th days were higher than in healthy animals. In animals with CKD, signs of epidermal cell dystrophy, edema, and hemorrhages in the granulation tissue performing the wound defect were observed at all periods of the experiment (Pavlov et al., 2019). Circulatory disorders and inflammatory infiltration, retardation of reepithelialization and the formation of an extracellular matrix, accumulation of cellular decay products and proteases in the tissue fluid are characteristic of chronic wounds, including those occurring against the background of systemic diseases (Bodnár et al., 2018; Krzystek-Korpacka et al., 2019). The duration of the healing of such wounds is due to the predominance of the phase of inflammation in the regeneration process. We believe that in chronic wounds associated with CKD, a vicious circle of positive feedback is created between local factors promoting inflammation and the body's systemic response in the form of proinflammatory cytokine production.

Thus, concomitant CKD disrupts the normal course of the wound healing process. Against the background of systemic inflammation, the wound transitions from an acute injury to a chronic one. Changes in the mechanisms of intercellular interactions, regulated by interleukins and

growth factors, led to disturbances in the structural organization in the damaged area.

Conclusion

Our study showed that concomitant CKD created an unfavourable background for skin wound healing in rats. Violation of the dynamics of production of IL-1 β , IL-4, IL-6, IL-10, as well as bFGF and VEGF caused longer healing of injuries with a decrease in the rate of reepithelialization of wounds, the number of fibroblasts and collagen deposition in granulation tissue, and an increase in the number of polymorphonuclear leukocytes. Disruption of intercellular and cell-matrix interactions, expressed in the predominance of pro-inflammatory mechanisms, was the basis for the mechanisms of the development of long-term non-healing wounds in animals with experimental CKD.

This study was funded by the Ministry of Health of Ukraine from the state budget (registration number 0120U101408).

References

- Ammirati A. L. (2020). Chronic kidney disease. *Revista da Associação Médica Brasileira*, 66, 3–9.
- Anders, H.-J. (2016). Of inflammasomes and alarmins: IL-1 β and IL-1 α in kidney disease. *Journal of the American Society of Nephrology*, 27(9), 2564–2575.
- Barreto, D. V., Barreto, F. C., Liabeuf, S., Temmar, M., Lemke, H.-D., Tribouilloy, C., Choukroun, G., Vanholder, R., & Massy, Z. A. (2010). Plasma interleukin-6 is independently associated with mortality in both hemodialysis and pre-dialysis patients with chronic kidney disease. *Kidney International*, 77(6), 550–556.
- Beyene, R. T., Deryberry, J. S. L., & Barbul, A. (2020). The effect of comorbidities on wound healing. *The Surgical Clinics of North America*, 100(4), 695–705.
- Bodnár, E., Bakondi, E., Kovács, K., Hegedűs, C., Lakatos, P., Robaszekiewicz, A., Regdon, Z., Virág, L., & Szabó, É. (2018). Redox profiling reveals clear differences between molecular patterns of wound fluids from acute and chronic wounds. *Oxidative Medicine and Cellular Longevity*, 2018, 5286785.
- Chao, C.-C., Wu, V.-C., Tan, C.-H., Wang, Y.-M., Tseng, M.-T., Wu, P.-C., Lin, Y.-H., Lin, W.-M., Wu, K.-D., & Hsieh, S.-T. (2011). Skin denervation and its clinical significance in late-stage chronic kidney disease. *Archives of Neurology*, 68(2), 200–206.
- Dissemond, J. (2017). Chronic leg ulcers. *Der Hautarzt*, 68(8), 614–620.
- Gal, P., Kilić, R., Mokry, M., Vidinsky, B., Vasilenko, T., Mozes, S., Bobrov, N., Tomori, Z., & Bober, J. (2008). Simple method of open skin wound healing model in corticosteroid-treated and diabetic rats: standardization of semi-quantitative and quantitative histological assessments. *Veterinarní Medicina*, 12, 652–659.
- Gupta, J., Mitra, N., Kanetsky, P. A., Devaney, J., Wing, M. R., Reilly, M., Shah, V. O., Balakrishnan, V. S., Guzman, N. J., Gimdt, M., Periera, B. G., Feldman, H. I., Kusek, J. W., Joffe, M. M., & Raj, D. S. (2012). Association between albuminuria, kidney function, and inflammatory biomarker profile in CKD in CRIC. *Clinical Journal of the American Society of Nephrology*, 7(12), 1938–1946.
- Hirano, T. (2021). IL-6 in inflammation, autoimmunity and cancer. *International Immunology*, 33(3), 127–148.
- Honnegowda, T. M., Kumar, P., Udupa, E. G. P., Kumar, S., Kumar, U., & Rao, P. (2015). Role of angiogenesis and angiogenic factors in acute and chronic wound healing. *Plastic and Aesthetic Research*, 2, 243–249.
- Li, F., Wang, M., Wang, J., Li, R., & Zhang, Y. (2019). Alterations to the gut microbiota and their correlation with inflammatory factors in chronic kidney disease. *Frontiers in Cellular and Infection Microbiology*, 9, 206.
- Kang, D. H., Joly, A. H., Oh, S. W., Hugo, C., Kerjaschki, D., Gordon, K. L., Mazzali, M., Jefferson, J. A., Hughes, J., Madsen, K. M., Schreiner, G. F., & Johnson, R. J. (2001). Impaired angiogenesis in the remnant kidney model: I. Potential role of vascular endothelial growth factor and thrombospondin-1. *Journal of the American Society of Nephrology*, 12, 1434–1447.
- Kondakov, I. I., Topchii, I. I., & Kirienko, O. M. (2013). Influence of glycerol on functional-morphological indicators of kidneys at modelling renal insufficiency in rats. *Ukrainian Journal of Nephrology and Dialysis*, 39, 14–20.
- Krzystek-Korpacka, M., Kędzior, K., Masłowski, L., Mierzchała, M., Bednarz-Misa, I., Bronowicka-Szydelko, A., Kubiak, J., Gacka, M., Plączkowska, S., & Gamin, A. (2019). Impact of chronic wounds of various etiology on systemic profiles of key inflammatory cytokines, chemokines and growth factors, and their interplay. *Advances in Clinical and Experimental Medicine*, 28(10), 1301–1309.
- Maroz, N., & Simman, R. (2014). Wound healing in patients with impaired kidney function. *The Journal of the American College of Clinical Wound Specialists*, 5(1), 2–7.

- Narazaki, M., & Kishimoto, T. (2018). The two-faced cytokine Il-6 in host defense and diseases. *International Journal of Molecular Sciences*, 19(11), 3528.
- Pavlov, S., Kumetchko, M., Litvinova, O., Babenko, N., Valilshchikov, N., & Shamas, O. (2019). Features of morphological changes in the skin during wound healing. *Journal of Morphological Sciences*, 2(2), 22–30.
- Pavlov, S., Babenko, N., Kumetchko, M., Litvinova, O., Semko, N., & Pavlova, O. (2019). Intercellular mediators in bone remodeling regulation in the experimental renal pathology. *Actualizaciones en Osteología*, 15(3), 180–190.
- Petreski, T., Piko, N., Ekart, R., Hojs, R., & Bevc, S. (2021). Review on inflammation markers in chronic kidney disease. *Biomedicines*, 9(2), 182.
- Robles-Mendez, J. C., Vazquez-Martinez, O., & Ocampo-Candiani, J. (2015). Skin manifestations of chronic kidney disease. *Actas Dermo-Sifiliográficas*, 106(8), 609–622.
- Romanova, Y., Laikov, A., Markelova, M., Khadiullina, R., Makseev, A., Hasanova, M., Rizvanov, A., Khaiboullina, S., & Salafutdinov, I. (2020). Proteomic analysis of human serum from patients with chronic kidney disease. *Biomolecules*, 10(2), 257.
- Querfeld, U., Mak, R. H., & Pries, A. R. (2020). Microvascular disease in chronic kidney disease: The base of the iceberg in cardiovascular comorbidity. *Clinical science*, 134(12), 1333–1356.
- Seth, A. K., De la Garza, M., Fang, R. C., Hong, S. J., & Galiano, R. D. (2013). Excisional wound healing is delayed in a murine model of chronic kidney disease. *PloS One*, 8(3), e59979.
- Sheng, W.-S., Xu, H.-L., Zheng, L., Zhuang, Y.-D., Jiao, L.-Z., Zhou, J.-F., ZhuGe, D.-L., Chi, T.-T., Zhao, Y.-Z., & Lan, L. (2018). Intrarenal delivery of bFGF-loaded liposome under guiding of ultrasound-targeted microbubble destruction prevent diabetic nephropathy through inhibition of inflammation. *Artificial Cells, Nanomedicine, and Biotechnology*, 46(2), 373–385.
- Souza, M. K., Neves, R. V. P., Rosa, T. S., Cenedeze, M. A., Arias, S. C. A., Fujihara, C. K., Bacurau, R. F. P., Câmara, N. O. S., Moraes, M. R., & Filho, A. P. E. S. (2018). Resistance training attenuates inflammation and the progression of renal fibrosis in chronic renal disease. *Life Sciences*, 206, 93–97.
- Summers, S. A., Phoon, R. K., Odobasic, D., Dewage, L., Kitching, A. R., & Holdsworth, S. R. (2011). Signal transducer and activation of transcription 6 (STAT6) regulates T helper type 1 (Th1) and Th17 nephritogenic immunity in experimental crescentic glomerulonephritis. *Clinical and Experimental Immunology*, 166, 227–234.
- Steen-Louws, C., Hartgring, S. A. Y., Popov-Celeketic, J., Lopes, A. P., de Smet, M. B. M., Eijkelkamp, N., Laféber, F. P. J. G., Hack, C. E., & van Roon, J. A. G. (2019). IL4-10 fusion protein: A novel immunoregulatory drug combining activities of interleukin-4 and interleukin-10. *Clinical and Experimental Immunology*, 195(1), 1–9.
- Stompór, T., Zdzienicka, A., Motyka, M., Dembińska-Kieć, A., Davies, S. J., & Sułowicz, W. (2002). Selected growth factors in peritoneal dialysis: Their relationship to markers of inflammation, dialysis adequacy, residual renal function, and peritoneal membrane transport. *Peritoneal Dialysis International*, 22(6), 670–676.
- Tanaka, S., Tanaka, T., & Nangaku, M. (2015). Hypoxia and dysregulated angiogenesis in kidney disease. *Kidney Diseases*, 1, 80–89.
- Vanholder, R., Annemans, L., Brown, E., Gansevoort, R., Gout-Zwart, J. J., Lameire, N., Morton, R. L., Oberbauer, R., Postma, M. J., Tonelli, M., Van Biesen, W., & Zoccali, C. (2017). Reducing the costs of chronic kidney disease while delivering quality health care: A call to action. *Nature Reviews, Nephrology*, 13, 393–409.
- Vlahovic, P., Cvetkovic, T., Savic, V., & Stefanovic, V. (2007). Dietary curcumin does not protect kidney in glycerol-induced acute renal failure. *Food and Chemical Toxicology*, 45(9), 1777–1782.
- Wang, C., Wang, M., Xu, T., Zhang, X., Lin, C., Gao, W., Xu, H., Lei, B., & Mao, C. (2019). Engineering bioactive self-healing antibacterial exosomes hydrogel for promoting chronic diabetic wound healing and complete skin regeneration. *Theranostics*, 9(1), 65–76.
- Zhu, Z. X., Sun, C. C., Ting, Z. Y., Wang, Y., Wang, T., Chi, L. S., Cai, W. H., Zheng, J. Y., Zhou, X., Cong, W. T., Li, X. K., & Jin, L. T. (2017). Hedgehog signaling contributes to basic fibroblast growth factor-regulated fibroblast migration. *Experimental Cell Research*, 355(2), 83–94.
- Zinatullin, R. M., Gizatullin, T. R., Pavlov, V. N., Kataev, V. A., Farhutdinov, R. R., & Baymurzina, J. L. (2014). A method for modeling a trophic wound in an experiment. *Russian Patent RF 2510083*.