



## Responses of the freshwater bivalve *Dreissena polymorpha* to 2,4,6-trinitrotoluene exposure: A biochemical and histopathological study

N. B. Yesipova, N. O. Khromykh, T. S. Sharamok, O. M. Marenkov, I. V. Drehval, O. O. Didur, A. Y. Savytsky  
Oles Honchar Dnipro National University, Dnipro, Ukraine

### Article info

Received 02.06.2025

Received in revised form  
22.06.2025

Accepted 16.07.2025

Oles Honchar Dnipro  
National University,  
Nauky av., 72,  
Dnipro, 49010, Ukraine.  
Tel.: +38-050-569-28-17.  
E-mail:  
yesipova.natalia  
@gmail.com

Yesipova, N. B., Khromykh, N. O., Sharamok, T. S., Marenkov, O. M., Drehval, I. V., Didur, O. O., & Savytsky, A. Y. (2025). Responses of the freshwater bivalve *Dreissena polymorpha* to 2,4,6-trinitrotoluene exposure: A biochemical and histopathological study. *Regulatory Mechanisms in Biosystems*, 16(3), e25110. doi:10.15421/0225110

Military operations and the associated pollution of the Ukrainian river ecosystems affect all aquatic inhabitants. Freshwater bivalves are environmentally important stress-sensitive filter feeders, but their adaptive capacity to explosives is currently poorly understood. The alien bivalve *Dreissena polymorpha* (zebra mussel), invaded the Dnieper River basin waters and has served as the model object to reveal the biochemical and histological effects of 2,4,6-trinitrotoluene (TNT) action. During chronic (27 days at 2.5 mg/L) exposure, the weight of the experimental mollusks decreased, while their mortality exceeded the control rate. TNT toxicity level of LC<sub>50</sub> for *D. polymorpha* was calculated by Probit analysis. Histopathological changes in the zebra mussel tissues were examined on the 10th and 27th days and showed the dependence on TNT exposure duration. In the gills, lamellae curvature and elongation, cilia degradation and loss, destruction of lamellar apical tips, and cellular abnormalities, such as epithelial cells dysplasia and karyolysis were detected. The hepatopancreas of the experimental zebra mussels demonstrated partially or completely destroyed acini, disruption of basement membrane, destruction of tubules, and digestive cells hypertrophy, hyperplasia, vacuolization, and necrosis. Long-term TNT exposure significantly elevated glutathione-S-transferase activity and malondialdehyde content in the *D. polymorpha* hepatopancreas and gills, marking oxidative stress and indicating accumulation and/or biodegradation of TNT in the mollusks' tissues. The results are discussed regarding the specificity of some identified biomarkers as indicators of TNT action. Overall, the biochemical and histopathological responses reflected the metabolic adaptations of zebra mussels to survive in a TNT-polluted environment. Study results indicated sensitivity of *D. polymorpha* to 2,4,6-trinitrotoluene, while suggested the mollusk's potential for bioremediation in freshwater ecosystems contaminated with explosives.

**Keywords:** zebra mussel; TNT; LC<sub>50</sub>; histopathology; biomarkers; GST; MDA.

### Introduction

Large-scale hostilities on the territory of Ukraine during the Russian aggression have led to the physical destruction of several large freshwater ecosystems and caused irreparable damage to the environment. Recent studies revealed the destruction of hydraulic structures, pollution of watercourses due to intense fighting and fires, damage to water supply infrastructure, and mass deaths of aquatic organisms in Kyiv Region (Kireitseva & Tsyhanenko-Dziubenko, 2025). River habitat damage and excessive pollution are causing the catastrophic ecological situation in Southern Ukraine. War exacerbates environmental pollution with heavy metals and nitroaromatic compounds, which are released during explosions and accumulate in critical volumes in the combat zone and adjacent areas (Zulfigarov et al., 2023). Additional harm of military conflicts is the significant exposure of the environment to the toxic compounds from unexploded ordnance and post-explosion by-products (Chatterjee et al., 2017). The coexistence of various types of organic (nitroaromatic compounds) and inorganic (heavy metals) pollutants in contaminated areas complicates the cleanup and restoration of the environment (Tauqeer et al., 2021). Contamination of water bodies with explosives causes toxic effects on biota (Sharamok et al., 2024) decreasing the number of flora and fauna in the polluted aquatic ecosystems.

Among the chemical explosive materials, 2,4,6-trinitrotoluene (TNT) is considered the most common for the production of ammunition (Chatterjee et al., 2017). TNT metabolites, namely 2-amino-4,6-dinitrotoluene (2-ADNT) and 4-amino-2,6-dinitrotoluene (4-ADNT), occur during the biotic transformation of 2,4,6-trinitrotoluene in the environment. These compounds are highly toxic and carcinogenic, implementing the mechanism of toxicity through the ability to cause oxidative stress and the formation of reactive oxygen species in the target biota (Maser et al., 2023). The long-term danger of TNT and its transformation products to aquatic ecosystems was shown by relict ammunition from the Second World War in the coastal waters of the

Baltic Sea. It was found that one or more explosive compounds were present in 98.0% of the organisms studied, including plankton, macroalgae, sponges, mollusks, echinoderms, polychaetes, sea anemones, crustaceans, and fish, including commercially important fish species (Beck et al., 2022; Maser et al., 2024).

Mollusks, including bivalves, are often the test subjects in monitoring and laboratory studies of the toxic effects of pollutants on aquatic organisms. In particular, the state of anthropogenic pollution of various areas of the Mediterranean coast was assessed using a complex of biochemical and functional indicators of the mussel *Mytilus galloprovincialis* (Benali et al., 2015; Balbi et al., 2017; Boudjema et al., 2023). In addition, a study of bioaccumulation processes in aquatic organisms showed the presence of 20 chemical compounds in the tissues of *M. galloprovincialis*, such as pharmaceuticals and personal care products, pesticides, and perfluoroalkyl substances (Álvarez-Ruiz et al., 2021). The impact of military pollution and hostilities on freshwater inhabitants, including malacofauna, is less studied. Such research is relevant in Ukraine, as exemplified by studies of ecotoxicological reactions of widely distributed *Planorbarius corneus* on the water pollution by zinc (Babych et al., 2022) and nickel ions (Uvayeva et al., 2023). Recently, the physiological and biochemical mechanisms of resistance of freshwater mollusks *P. corneus* and *Viviparus viviparus* to the heavy metals, including lead from ammunition and explosives, were revealed (Tsyhanenko-Dziubenko et al., 2024). To assess the response of biota to environmental stress, the biomarkers offer a convenient way (Balbi et al., 2017). In particular, malondialdehyde, the end product of lipid peroxidation, serves as a marker of oxidative stress (García et al., 2020). Glutathione-S-transferase, a key enzyme in phase II detoxification, is a biomarker of neutralization of the xenobiotics by their conjugation to an endogenous substrate, thus facilitating their elimination (Dasari et al., 2018; Lozano et al., 2024).

The bivalve mollusk *Dreissena polymorpha* Pallas, 1771 (zebra mussel) is the representative of the Ponto-Caspian zoogeographical

complex (Anistratenko et al., 2017), but currently has invaded the European (Dzierżyńska-Białończyk et al., 2018; Doelle et al., 2020), including Ukrainian rivers (Fedonenko et al., 2017). Zebra mussels are environmentally important filter-feeding bivalves contributing to water purification due to their tremendous filtering capacity. The present study aimed to integrate biochemical and histopathological markers in the *D. polymorpha* tissues for a more complete understanding the toxic effects of TNT and for assessing the potential of these bivalves for self-purification of water bodies from military pollutants.

## Materials and methods

The toxicological study was conducted in June 2025 in the Biology Research Institute of Oles Honchar Dnipro National University using the bivalve zebra mussel (*Dreissena polymorpha* Pallas, 1771; Myida, Dreissenidae) as the test-object. Healthy sexually mature zebra mussels were taken from the shallow water of Samara River (in the Dnieper basin) and placed in 20-liter aquariums with aerated settled tap water for 10 days before the experiment. Both the control and experimental groups of mollusks were fed every day throughout the acclimation and TNT exposure. Model aquatic environments in the five-liter aquariums were contaminated by adding an appropriate amount of 2,4,6-trinitrotoluene, obtained as previously described (Khromykh et al., 2023).

Toxicity level of TNT for *D. polymorpha* was determined according to Schoenke et al. (2025), identifying the concentration which caused mortality of 50% of the mollusks (LC<sub>50</sub>) in concentrations range 2.5–25.0 mg/L during 24, 48, 72, and 96 hours; testing was repeated three times, using 20 zebra mussels for each test. TNT chronic exposure lasted 27 days under concentration of 2.5 mg/L, maintained by weekly replacement of aqueous medium. At the end of experiment, mollusk number and morphometric parameters (weight, length, and width) were determined, and the samples of mollusk tissues (gills and hepatopancreas) for biochemical assays were collected and placed in a freezer at –20 °C. Tissue samples for histological assays were collected on the 10th and 27th days of experiment and fixed in 10% formalin solution.

Histological preparations of the control and experimental zebra mussels were made using paraffin blocks with subsequent sectioning by automatic microtome PM100A (China, 2020) and staining with hematoxylin-eosin. Microscope Ulab XY-B2TLED 78 (China, 2022) at a magnification of 400×, equipped with a digital camera Sciencelab T500 5.17M (China, 2022), was used for observation and photo fixation of the histological preparations. Ten fields of view on the 10 preparations of both hepatopancreas and gills of *D. polymorpha* were examined; number of histopathological lesions was expressed as a percentage of total observed tissue elements.

Detoxifying ability of *D. polymorpha* hepatopancreas and gills was assessed as glutathione-S-transferase (GST, EC 2.5.1.18) activity, determined at 340 nm by the method (Habig & Jakoby, 1981) using 2,4-dinitrochlorobenzene (DNCB) as a substrate. GST activity was expressed as μM DNCB/s g tissue. The intensity of lipid peroxidation (LPO) processes in the tissues of zebra mussel was assessed according to Garsia et al. (2020), by measuring malondialdehyde (MDA)

content at 532 nm after reaction with thiobarbituric acid at 100 °C, and expressed as nmol MDA/g tissue.

All bioassays were conducted in at least three replicates. The experimental results were analyzed using one-way ANOVA and presented as mean ± standard deviation (SD). The multivariate analysis and multiple comparison of samples by Tukey's test were used; all differences of means were statistically significant at P < 0.05. Probit analysis was applied to calculate LC<sub>50</sub> of TNT.

## Results

During a long-term TNT exposure, the treated zebra mussels exhibited significant differences compared to the control group in mortality (3.56 times higher) and wet weight (9.6% lower), while other biometric parameters remained largely unchanged (Table 1).

**Table 1**

Changes in mortality, wet weight, shell length and width of *D. polymorpha* due to chronic TNT action (x ± SD, n = 50)

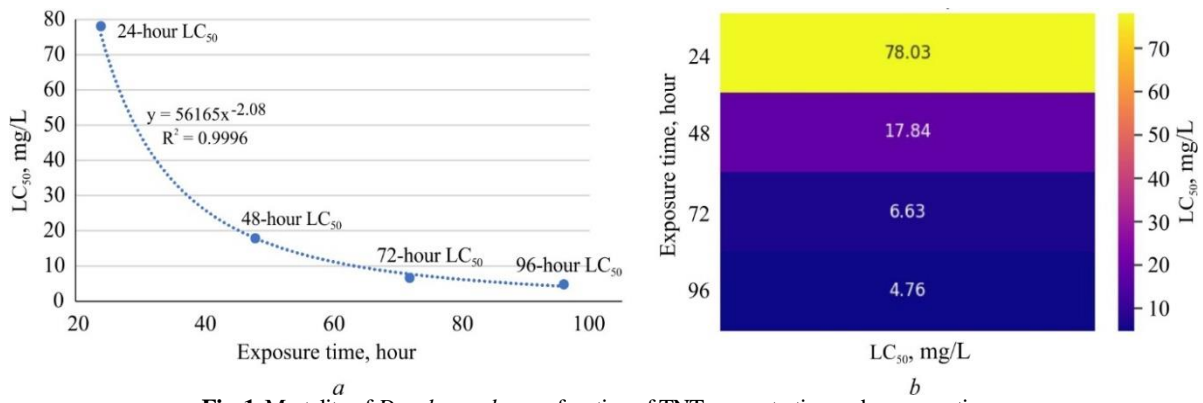
Options	Weight, g	Length, cm	Width, cm	Mortality, %
Control	0.91 ± 0.26	1.74 ± 0.31	0.89 ± 0.18	4.41 ± 0.18
TNT, 27 days	0.83 ± 0.29*	1.71 ± 0.27	0.91 ± 0.18	15.68 ± 0.83***

Note: \* – P ≤ 0.05, \*\*\* – P ≤ 0.001 compared to control.

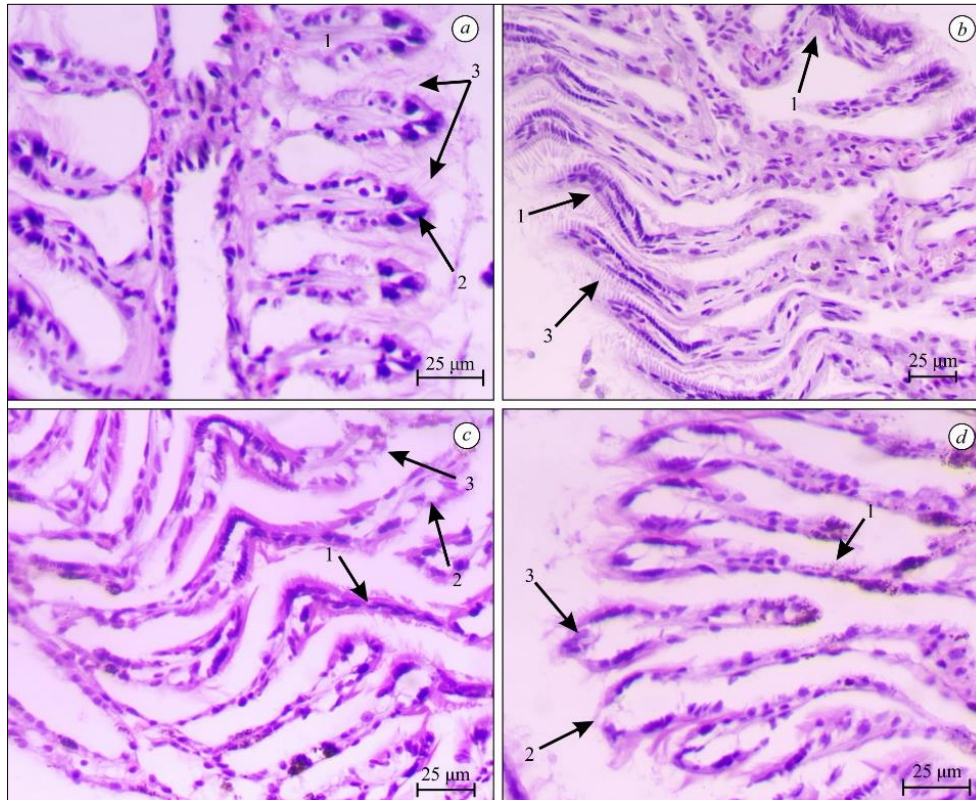
Study of TNT toxicity for *D. polymorpha* revealed the dose dependent decrease in survival during 24, 48, 72, and 96 hours of exposure. Probit analysis of data obtained showed a generalized dependence curve of zebra mussel mortality for all exposure options (Fig. 1a) and allowed calculating median LC<sub>50</sub> values along the exposure period (Fig. 1b).

Histological preparations of the control zebra mussel gills (Fig. 2a) demonstrated two rows of almost uniform club-shaped lamellae, lined with epithelial cells containing clearly defined nuclei and surrounded by a dense layer of cilia. Exposure to TNT for 10 days caused lamellae curvature and elongation, and cilia layer thinning or even loss (Fig. 2b). On the 27th day of TNT exposure, signs of lamellar degradation (thinning and disappearance of the lumen), destruction of the epithelium at the ends of the lamellae and cilia disappearance, as well as dysplasia, vacuolization and karyolysis of epithelial cells were observed. (Fig. 2c, 2d).

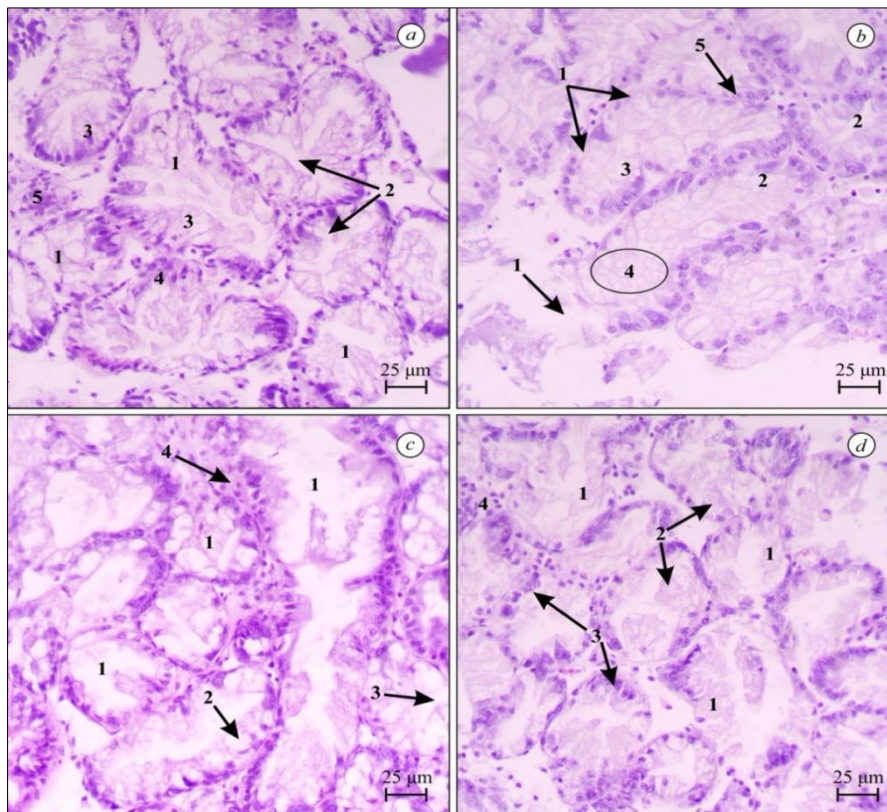
Hepatopancreas (digestive gland) structure of the *D. polymorpha*, which is composed of cell clusters (acinus), was represented by acini of various sizes surrounded by connective tissue, and the acinar structural elements, such as tubules with narrow lumina, digestive cells, and lime cells on the histological preparations of control group (Fig. 3a). The zebra mussels' exposure to TNT for 10 days caused destruction of basement membrane, irregularity of lumina in the tubules, and digestive cells hypertrophy or hyperplasia (Fig. 3b). The severity of histopathological lesions in the digestive gland increased by 27th day, including the appearance of destroyed acini, digestive cells vacuolization and necrosis (Fig. 3c). However, small acini with intact structure were observed on several preparations at the end of the experiment (Fig. 3d).



**Fig. 1.** Mortality of *D. polymorpha* as a function of TNT concentration and exposure time: *a* – dynamics of LC<sub>50</sub> across exposure time, *b* – heat map of mortality and LC<sub>50</sub> by time and dose



**Fig. 2.** Histological structure of *D. polymorpha* gills in control (*a*: 1 – lamellae, 2 – epithelial cells of lamellar apical tips, 3 – cilia layer) and under TNT action: *b* – after 10 days (1 – elongated and curved lamellae, 3 – cilia degradation), *c* and *d* – after 27 days (*c*: 1 – lamellae destruction, 2 – epithelial cells dysplasia, 3 – cilia disappearance; *d*: 1 – lamellae degradation, 2 – lamellar apical tips destruction, 3 – epithelial cells karyolysis)



**Fig. 3.** Histological structure of *D. polymorpha* hepatopancreas in control (a: 1 – acinus, 2 – acinar tubules with lumina, 3 – digestive cells, 4 – lime cells assembled to crypts, 5 – connective tissue, and under TNT action), after 10 days (b: 1 – destroyed basement membrane, 2 – irregular lumina of acinar tubules, 3 – digestive cells hypertrophy, 4 – digestive cells hyperplasia, 5 – lime cells vacuolization), and after 27 days (c: 1 – destroyed acinus, 2 – digestive cells vacuolization, 3 – digestive cells necrosis, 4 – connective tissue proliferation; d: 1 – small intact acini with tubules, 2 – digestive cells, 3 – lime cells, 4 – connective tissue)

The long-term exposure to TNT altered morphometric characteristics of *D. polymorpha* tissues. Lamellae length in the gills increased exceeding the control level by 127.7% and 132.3%, respectively, on days 10 and 27; the hepatopancreas showed minor variations in acinus average area, but significant differences in the intact acini number (Table 2).

**Table 2**  
Changes in lamellae length, acini area, and intact acini number in *D. polymorpha* due to TNT chronic action ( $x \pm SD$ ,  $n = 100$ )

Options	Gills		Hepatopancreas (digestive gland)	
	lamellae length, $\mu\text{m}$	average acinus area, $\mu\text{m}^2$	average	number of intact acini, %
Control	108 $\pm$ 15 <sup>a</sup>	12105 $\pm$ 1557 <sup>a</sup>	12105 $\pm$ 1557 <sup>a</sup>	89.5 $\pm$ 2.4 <sup>a</sup>
TNT, 10 days	246 $\pm$ 26 <sup>b</sup>	12187 $\pm$ 1753 <sup>a</sup>	12187 $\pm$ 1753 <sup>a</sup>	26.1 $\pm$ 1.1 <sup>b</sup>
TNT, 27 days	250 $\pm$ 26 <sup>b</sup>	11389 $\pm$ 1634 <sup>a</sup>	11389 $\pm$ 1634 <sup>a</sup>	34.2 $\pm$ 1.4 <sup>c</sup>

Note: different letters within a column indicate significant differences in mean values by Tukey's test ( $P \leq 0.05$ ).

Biochemical assays revealed the significant glutathione-S-transferase activation as well as increase in MDA content in *D. polymorpha* gills and hepatopancreas due to 27 days of 2,4,6-trinitrotoluene exposure (Table 3).

**Table 3**  
Changes in MDA content and GST activity in *D. polymorpha* tissues due to chronic TNT exposure ( $x \pm SD$ ,  $n = 5$ )

Options	Hepatopancreas	Gills
Malondialdehyde content, nmol/g tissue		
Control	17.6 $\pm$ 0.16	19.4 $\pm$ 0.16
TNT	18.8 $\pm$ 0.14*	24.4 $\pm$ 0.13***
Glutathione-S-transferase activity, nmol CDNB/s g tissue		
Control	49.6 $\pm$ 0.54	39.9 $\pm$ 0.85
TNT	81.5 $\pm$ 0.46***	91.4 $\pm$ 0.49***

Note: see Table 1.

Glutathione-S-transferase activity increased most in the gills of treated zebra mussels (twice compared to control) and less significantly in the hepatopancreas (64.3% higher than control). The malondialdehyde content exceeded the control most in the gills (by 25.8%), while it increased slightly in the hepatopancreas (by 6.8% only).

## Discussion

Bivalve data improve the water quality and ecosystem health assessments by indicating pollutant impacts through these filter feeders' contact with most contaminants entering water bodies. Monitoring studies with transplanting blue mussels (*Mytilus edulis*) into an explosively contaminated area near dumped munitions in the Baltic Sea showed accumulation of TNT and its metabolites 2-ADNT and 4-ADNT in the mollusks at 31.0–131.3 ng/g (Strehse et al., 2017) and even 250.0 ng/g wet weight (Maser et al., 2024). The effects of explosives on freshwater mollusks are poorly studied, although Tollett & Kolb (2005) identified seven explosive compounds in the tissue samples of *Lampsilis hydiana* and *Toxolasma parvus* collected near a military training site in the United States. The bivalve *D. polymorpha* was proposed by Binelli et al. (2015) as a reference organism for bio-monitoring of freshwater bodies, as the rapid response of this mollusk to pollution allows the rapid identification of their negative effects.

Determining the LC<sub>50</sub> levels of chemical pollutants for different aquatic species is an important tool in assessing and predicting the state of freshwater ecosystems and biodiversity (Schoenke et al., 2025). The significant differences in LC<sub>50</sub> indicators of heavy metals (ranging from 2 to 10 times) were shown by Harbar et al. (2021) even for two vicarious genetic *Planorbis corneus* allopopulations. The 96-hour TNT toxicity level for *D. polymorpha* in our study coincides with the laboratory research on blue mussels' viability during 96 hours of TNT exposure at concentrations of 0.31–10.00 mg/L (Maser et al., 2024), and with reported (Koske et al., 2019) TNT toxicity values for marine fish in range 0.8–7.6 mg/L. The decrease in survival of the zebra

mussels due to chronic TNT exposure, and morphometry changes in the shells correspond to the patterns of stress-induced reaction of other mollusks. For example, populations of Black Sea mussels *Mytilus galloprovincialis* that were stressed due to desalination of water by river runoff had lower abundance, average mass and productivity, as well as lower survival rates (Stadnichenko, 2022). The dose-dependent mortality growth was detected for the freshwater mussel *Lamellidens marginalis* exposed to the pesticide chlorpyrifos (Hossain et al., 2023).

The severity of histopathological lesions in the *D. polymorpha* tissue structure demonstrated the dependence on the duration of 2,4,6-trinitrotoluene exposure. The gill lamellae curvature and elongation, and cilia loss appeared within 10 days of toxic action and continued to worsen, until complete degradation of the lamellae on the 27th day. On the other hand, destruction of lamellar apical tips, and some cellular abnormalities, such as epithelial cells dysplasia and karyolysis, were detected at the end of the experiment. The results obtained confirm the vulnerability of bivalve gills due to direct contact with xenobiotics in aquatic environment. Similar pathologies of epithelial cells and ciliated layer of the bivalve mollusk gills were found by other authors, in particular, in *M. galloprovincialis* after long-term exposure to insecticides Calypso (Stara et al., 2020) and thiacloprid (Stara et al., 2021), and in freshwater *L. marginalis* after exposure to oil effluent (Balamurugan & Subramanian, 2021). At the same time, severe histopathological effects such as curvature and elongation of gill lamellae, which were observed in *D. polymorpha* under chronic exposure to TNT, have not been reported in the scientific data. Pathological changes in the lamellae, such as their thinning and disappearance of the lumen, are a sign of degradation, which makes hemolymph circulation and gas exchange in the mollusk gills impossible. The similar reduction of interlamellar space and fusion of filaments, and nuclei degeneration were found in the gills of *L. marginalis* exposed to pesticide imidacloprid (Dethé & Bhikan Ahire, 2023). Therefore, elongation of gill lamellae in zebra mussels could be a compensatory mechanism to maintain the respiratory and other crucial functions in conditions of large-scale gill damage due to chronic TNT action. Further studies are needed to confirm pathological curvature and elongation of lamellae as a specific response of *D. polymorpha* to TNT, as well as to clarify the physiological role of lamellae elongation.

The damage to the hepatopancreas of zebra mussels after 10 days exposure to TNT included partial disruption of the acinar basement membrane, destruction of the integrity of the lumina in the tubules, and hypertrophy or hyperplasia of digestive cells. The 27-days toxic influence led to the appearance of partially or completely destroyed acini, tubular atrophy, and digestive cells vacuolization and necrosis. A similar set of pathological lesions was observed by Dethé & Bhikan Ahire (2023) in the digestive gland of freshwater bivalve *L. marginalis* exposed to the pesticide imidacloprid, which caused disruption of the basement membrane and digestive tubules, deterioration of the lumina, and vacuolization of cytoplasm. The exposure of *L. marginalis* to oil effluent resulted in significant histopathological alterations of the digestive gland, such as detachment of the glandular epithelium and disruption of its integrity, as well as the compaction of the lumina (Balamurugan & Subramanian, 2021). Notable degeneration of digestive tubules, epithelial cell necrosis, and hemolytic infiltration in the connective tissue were revealed in the digestive glands of Asiatic clam *Corbicula fluminea* due to treatment with imidacloprid (Shan et al., 2020). Recent studies of responses of the freshwater mussel *Unio delicatus* to the toxic effects of pesticides established in the digestive gland the duration-dependent degeneration of tubules, degeneration and loss of interstitial tissue, and tubular necrosis due to emamectin exposure (Bayrak et al., 2025), and tubule degeneration and even tubule loss after exposure to sublethal concentrations of acetamiprid (Tessi et al., 2025).

In addition to the results discussed results in the study, several preparations which characterized the *D. polymorpha* hepatopancreas at the end of TNT exposure demonstrated groups of small intact acini that had the appropriate acinar elements, namely branched tubules with clear lumina, the digestive and lime cell, and were surrounded by connective tissue. Such a trend suggests a gradual restoration of the

zebra mussel hepatopancreas, indicating the significant adaptive capacity of *D. polymorpha* to chronic TNT exposure. Our finding is in line with data of Balamurugan & Subramanian (2021) on the gradual restoration of the digestive gland structure and granular architecture of its epithelium in *L. marginalis* during the recovery period after cessation of exposure to oil effluent.

In ecotoxicological studies, biomarkers are a useful tool because they function as early warning indicators of stress (Barrick et al., 2016). In particular, malondialdehyde (a byproduct of lipid peroxidation) and various enzymatic biomarkers are commonly used for assessing and predicting contaminated sites in aquatic ecosystems. Albergho et al. (2016) consider lipid metabolism disorders as one of the most important biochemical reactions due to environmental pollution. In the integrated indicators, MDA and GST biomarkers (Boudjema et al., 2023), and acetylcholinesterase (AChE) and GST biomarkers (Benali et al., 2015) were used to monitor xenobiotic contamination and assess its impact on *M. galloprovincialis* populations in spatial and temporal studies. Maser et al. (2024) proposed to use the level of carbonyl reductase gene expression in blue mussel (*M. edulis*) tissues as a specific biomarker for detecting TNT contamination in the environment and conducting a risk assessment for both the ecosystem and the seafood consumer.

In our study, GST and MDA levels in *D. polymorpha* tissues served as biomarkers for altered metabolic processes resulting from long-term TNT exposure. The highest activation of glutathione-S-transferase in the zebra mussel gills suggests an effective TNT detoxification in the organs directly exposed to waterborne pollutants. Our findings are in line with data of Azevedo et al. (2015) on the multifunctionality of mollusk gills, which complement respiration and nutrient absorption with a crucial role in protection against water pollutants by activating phase I and II enzymes of xenobiotic detoxification. Results obtained coincide with heavily induced GST activity in the gills of *M. galloprovincialis* from the Algerian coast polluted with polychlorobiphenyls, polycyclic aromatic hydrocarbons, and heavy metals (Benali et al., 2017). At the same time, lower GST activation in the zebra mussel hepatopancreas may reflect the specific adaptive alterations of the digestive gland detoxifying system to chronic TNT exposure. This assumption is consistent with the study results on detoxification metabolism responses in the marine bivalve *Ruditapes philippinarum* exposed to several polycyclic aromatic hydrocarbons, where most of the 13 different isoforms of GST classified in mollusk tissues were expressed in digestive glands (Zhou et al., 2022).

Enhanced MDA content in tissues of TNT-treated *D. polymorpha* is in line with the reported two-fold increase in lipid peroxidation in gills and hepatopancreas of freshwater *L. marginalis* caused by the neonicotinoid pesticide imidacloprid (Dethé & Bhikan Ahire, 2023). The similar affected lipid peroxidation was revealed in the gills of *M. galloprovincialis* exposed to insecticide thiacloprid at environmentally relevant concentrations (Stara et al., 2021). High induction of lipid peroxidation process in the freshwater bivalve *Corbicula largillierti* was caused by pesticides glyphosate and imidacloprid (Lozano et al., 2024). Significant variations in malondialdehyde content was observed (Bayrak et al., 2025) in the gills and digestive gland of *U. delicatus* exposed to the insecticide emamectin. Our findings confirm the high ecological importance of bivalves noted by Albergho et al. (2016), which is related to their ability to withstand environmental changes thanks to subcellular systems adapted to accumulate and metabolize pollutants.

## Conclusion

The present study showed biochemical and histopathological responses of freshwater bivalve *D. polymorpha* (zebra mussel) to 2,4,6-trinitrotoluene (TNT) under long-term influence (27 days at 2.5 mg/L). The 96-hour toxicity level of TNT for *D. polymorpha* was calculated by Probit analysis as  $LC_{50} = 4.76$  mg/L. The duration-dependent nature of the toxic effect of TNT on the histological structure of zebra mussel gills and hepatopancreas (digestive gland) has been established. Histopathological lesions of gills due to TNT exposure coincide with the damage caused by many other chemical toxicants,

except for elongation and curvature of the gill lamellae in *D. polymorpha*, which may be a specific marker of TNT action, but requires additional research. The destructive alterations in the zebra mussel digestive gland were similar to the responses of other bivalves on xenobiotics, however, the appearance of small intact acini at the end of the chronic experiment may indicate process of recovery, which became possible due to adaptive changes in the mollusks. Elevated biochemical parameters and histopathological lesions of zebra mussel following chronic TNT exposure serve as the markers of stress and indicate the direction of adaptive changes of metabolic processes in mollusks. The relatively low mortality rate of zebra mussel in long-term experiments, strong GST activation in main detoxifying tissues, and the suggested possibility of hepatopancreas regeneration indicates the potential *D. polymorpha* for bioaccumulation and/or biodegradation of 2,4,6-trinitrotoluene in militarily contaminated freshwater environments.

This research was funded by the Ministry of Education and Science of Ukraine “Development of the measures of preserving and restoring of the aquatic ecosystems, affected by military actions”, grant number 0123U101856 (2023–2025).

The authors declare no conflicts of interest.

## References

- Albergamo, A., Rigano, F., Purcaro, G., Mauceri, A., Fasulo, S., & Mondello, L. (2016). Free fatty acid profiling of marine sentinels by nanoLC-EI-MS for the assessment of environmental pollution effects. *Science of the Total Environment*, 571, 955–962.
- Álvarez-Ruiz, R., Picó, Y., & Campo, J. (2021). Bioaccumulation of emerging contaminants in mussel (*Mytilus galloprovincialis*): Influence of microplastics. *Science of the Total Environment*, 801, 149673.
- Anistratenko, V., Khaliman, I. A., & Anistratenko, O. (2017). Mollusks of the Utyuk Liman (Sea of Azov): A review of species composition with remarks on distribution and ecology. *Biology Bulletin*, 44(8), 913–921.
- Azevedo, C. C., Guzmán-Guillén, R., Martins, J. C., Osório, H., Vasconcelos, V., da Fonseca, R. R., & Campos, A. (2015). Proteomic profiling of gill GSTs in *Mytilus galloprovincialis* from the North of Portugal and Galicia evidences variations at protein isoform level with a possible relation with water quality. *Marine Environmental Research*, 110, 152–161.
- Babych, Y., Khlystau, N., Stadnychenko, A., Ikonnikova, Y., & Uvayeva, O. (2022). Effect of zinc ions on the lung and cutaneous diffusive respiration of the great ramshorn *Planorbis corneus* allospecies (Mollusca: Gastropoda: Pulmonata: Planorbidae) of the Ukrainian river network. *Folia Malacologica*, 30(3), 135–142.
- Balamurigan, S., & Subramanian, P. (2021). Histopathology of the foot, gill and digestive gland tissues of freshwater mussel, *Lamellidens marginalis* exposed to oil effluent. *Austin Journal of Environmental Toxicology*, 7(1), 1033.
- Balbi, T., Fabbri, R., Montagna, M., Camisassi, G., & Canesi, L. (2017). Seasonal variability of different biomarkers in mussels (*Mytilus galloprovincialis*) farmed at different sites of the Gulf of La Spezia, Ligurian Sea, Italy. *Marine Pollution Bulletin*, 116(1–2), 348–356.
- Barrick, A., Châtel, A., Marion, J.-M., Perrein-Ettajani, H., Bruneau, M., & Mouneyrac, C. (2016). A novel methodology for the determination of biomarker baseline levels in the marine polychaete *Hediste diversicolor*. *Marine Pollution Bulletin*, 108(1–2), 275–280.
- Beck, A., Gledhill, M., Kampmeier, M., Feng, C., Schlosser, C., Greinert, J., & Achterberg, E. (2022). Explosives compounds from sea-dumped relic munitions accumulate in marine biota. *Science of the Total Environment*, 806(4), 151266.
- Benali, I., Boutiba, Z., Grandjean, D., de Alencastro, L. F., Rouane-Hacene, O., & Chèvre, N. (2017). Spatial distribution and biological effects of trace metals (Cu, Zn, Pb, Cd) and organic micropollutants (PCBs, PAHs) in mussels *Mytilus galloprovincialis* along the Algerian west coast. *Marine Pollution Bulletin*, 115(1–2), 539–550.
- Benali, I., Boutiba, Z., Merabet, A., & Chèvre, N. (2015). Integrated use of biomarkers and condition indices in mussels (*Mytilus galloprovincialis*) for monitoring pollution and development of biomarker index to assess the potential toxic of coastal sites. *Marine Pollution Bulletin*, 95(1), 385–394.
- Binelli, A., Della Torre, C., Magni, S., & Parolini, M. (2015). Does zebra mussel (*Dreissena polymorpha*) represent the freshwater counterpart of *Mytilus* in ecotoxicological studies? A critical review. *Environmental Pollution*, 196, 386–403.
- Boudjema, K., Moulai-Mostefa, N., & Badis, A. (2023). Baseline levels of integrated biomarker response index (IBR) in *Mytilus galloprovincialis* (Lamarck, 1819) of Bou Ismail bay for monitoring Algerian Bays (Mediterranean Sea). *Marine Pollution Bulletin*, 192, 115022.
- Dasari, S., Ganjavi, M. S., Yellanurkonda, P., Basha, S., & Meriga, B. (2018). Role of glutathione S-transferases in detoxification of a polycyclic aromatic hydrocarbon, methylcholanthrene. *Chemico-Biological Interactions*, 294, 81–90.
- Dethe, V. D., & Bhikan Ahire, P. (2023). Evaluation of Imidacloprid-induced toxicity and lipid peroxidation in the freshwater bivalve, *Lamellidens marginalis*. *International Journal of Aquatic Biology*, 11(2), 124–130.
- Doelle, K., & Kurzmann, D. E. (2020). The freshwater mollusk *Dreissena polymorpha* (zebra mussel) – a review: Living, prospects and jeopardies. *Asian Journal of Environment and Ecology*, 13(2), 1–17.
- Dzierżyńska-Białończyk, A., Jermacz, L., Maćkiewicz, T., Gajewska, J., & Kobak, J. (2018). Mechanisms and impact of differential fouling of the zebra mussel *Dreissena polymorpha* on different unionid bivalves. *Freshwater Biology*, 63(7), 687–699.
- Fedonenko, O., Yakovenko, V., Ananieva, T., Sharamok, T., Yesipova, N., & Marenkov, O. (2017). Fishery and environmental situation assessment of water bodies in the Dnipropetrovsk Region of Ukraine. *World Scientific News*, 98(1), 1–105.
- Garcia, D., Lima, D., da Silva, D. G. H., & de Almeida, E. A. (2020). Decreased malondialdehyde levels in fish (*Astyanax altiparanae*) exposed to diesel: Evidence of metabolism by aldehyde dehydrogenase in the liver and excretion in water. *Ecotoxicology and Environmental Safety*, 190, 110107.
- Habig, W. H., & Jakoby, W. B. (1981). Assays for differentiation of glutathione S-transferases. *Methods in Enzymology*, 77, 398–405.
- Harbar, O., Harbar, D., Stadnychenko, A., & Babych, Y. (2021). Ecotoxicological responses of two *Planorbis corneus* s. lato (Mollusca, Gastropoda) allospecies to exposure of heavy metals. *International Journal of Aquatic Biology*, 9(6), 423–431.
- Hossain, M. A., Sarker, T. R., Sutradhar, L., Hussain, M., & Iqbal, M. M. (2023). Toxic effects of chlorpyrifos on the growth, hemocytes counts, and vital organ's histopathology of freshwater mussel, *Lamellidens marginalis*. *Journal of King Saud University – Science*, 35(2), 102482.
- Khromykh, N. O., Marenkov, O. M., Sharamok, T. S., Anishchenko, A. O., Yesipova, N. B., Nesterenko, O. S., Kurchenko, V. O., & Mylostyyvi, R. V. (2023). Simulating TNT (2,4,6-trinitrotoluene) elimination in the water pond inhabited by freshwater alga of the *Rhizoclonium* genus. *Regulatory Mechanisms in Biosystems*, 14(3), 365–369.
- Kireitseva, H., & Tsyhanenko-Dziubenko, I. (2025). Ecological assessment of military actions impacts on the Kyiv Region hydronetwork and strategies for aquatic ecosystem restoration. *Collection of Scientific Publications NUS*, 1, 199–207.
- Koske, D., Goldenstein, N. I., & Kammann, U. (2019). Nitroaromatic compounds damage the DNA of zebrafish embryos (*Danio rerio*). *Aquatic Toxicology*, 217, 105345.
- Lozano, V. L., Paolucci, E. M., Sabatini, S. E., Noya Abad, T., Muñoz, C., Liquin, F., Hollert, H., & Sylvester, F. (2024). Assessing the impact of Imidacloprid, glyphosate, and their mixtures on multiple biomarkers in *Corbicula largillierii*. *Science of the Total Environment*, 942, 173685.
- Maser, E., Andresen, K., Bünnig, T., Clausen, O., Wichert, U., & Strehse, J. (2023). Ecotoxicological risk of world war relic munitions in the sea after low- and high-order blast-in-place operations. *Environmental Science and Technology*, 57(48), 20169–20181.
- Maser, E., Bünnig, T., & Strehse, J. (2024). Environmental and human toxicology studies on explosive chemicals leaking from submerged munitions. *Propellants, Explosives, Pyrotechnics*, 49(4), e202300181.
- Schoenke, V. S. A. M., Wang, J., Van den Brink, P. J., & Hendriks, A. J. (2025). Assessing chronic effects of chemical pollution on biodiversity using mean species abundance relationships. *Environmental Toxicology and Chemistry*, 44(4), 1134–1141.
- Shan, Y., Yan, S., Hong, X., Zha, J., & Qin, J. (2020). Effect of Imidacloprid on the behavior, antioxidant system, multixenobiotic resistance, and histopathology of Asian freshwater clams (*Corbicula fluminea*). *Aquatic Toxicology*, 218, 105333.
- Sharamok, T. S., Khromykh, N. O., Yesipova, N. B., Marenkov, O. M., Koptieva, S. D., Korzhenevska, P. O., & Holub, I. V. (2024). Study on TNT toxic effects on the functional state of hydrobionts in the model contaminated water pond. *Journal of Chemistry and Technologies*, 32(3), 518–527.
- Stadnychenko, S. V. (2022). Population structure of the mussel *Mytilus galloprovincialis* from bottom settlements in the river water transformation zones of the north-western part of the Black Sea. *Morsky Ekologichny Zhurnal*, 1–2, 99–107.
- Stara, A., Pagano, M., Albano, M., Savoca, S., Di Bella, G., Albergamo, A., Koutkova, Z., Sandova, M., Velisek, J., Fabrello, J., Matozzo, V., & Faggio, C. (2021). Effects of long-term exposure of *Mytilus galloprovincialis* to thiacloprid: A multi-biomarker approach. *Environmental Pollution*, 289, 117892.

- Stara, A., Pagano, M., Capillo, G., Fabrello, J., Sandoval, M., Vazzana, I., Zuskova, E., Velisek, J., Matozzo, V., & Faggio, C. (2020). Assessing the effects of neonicotinoid insecticide on the bivalve mollusc *Mytilus galloprovincialis*. *Science of the Total Environment*, 700, 134914.
- Strehse, J. S., Appel, D., Geist, C., Martin, H.-J., & Maser, E. (2017). Biomonitoring of 2,4,6-trinitrotoluene and degradation products in the marine environment with transplanted blue mussels (*M. edulis*). *Toxicology*, 390, 117–123.
- Tauqeer, H. M., Karczewska, A., Lewińska, K., Fatima, M., Khan, S. A., Farhad, M., Turan, V., Ramzani, P. M. A., & Iqbal, M. (2021). Environmental concerns associated with explosives (HMX, TNT, and RDX), heavy metals and metalloids from shooting range soils: Prevailing issues, leading management practices, and future perspectives. In: Hasanuzzaman, M., & Prasad, M. N. V. (Eds.). *Handbook of bioremediation. Physiological, molecular and biotechnological interventions*. Academic Press, Pp. 569–590.
- Tessi, D. R. Y., Arslan Yüce, P., Gül, G., Dinçel, A. S., & Günel, A. Ç. (2025). How acetamiprid induced toxicity on freshwater mussel: Biomarker and histopathological responses? *Pesticide Biochemistry and Physiology*, 209, 106362.
- Tsyhanenko-Dziubenko, I., Šerevičienė, V., & Ustymenko, V. (2024). Dissecting biochemical mechanisms that mediate tolerance to military chemical stressors in diverse malacological systems. *Environmental Problems*, 9(1), 51–58.
- Ubani-Rex, O. A., Saliu, J. K., & Bello, T. H. (2017). Biochemical effects of the toxic interaction of copper, lead and cadmium on *Clarias gariepinus*. *Journal of Health and Pollution*, 7(16), 38–48.
- Uvayeva, O., Ikonnikova, Y., & Stadnychenko, A. (2023). Effect of nickel ions on ecotoxicological responses of the great ramshorn *Planorbis corneus* allospecies (Mollusca: Gastropoda: Pulmonata: Planorbidae) of the Ukrainian river network. *Folia Malacologica*, 31(3), 168–174.
- Zhou, Y., Yao, L., Pan, L., & Wang, H. (2022). Bioaccumulation and function analysis of glutathione-S-transferase isoforms in Manila clam *Ruditapes philippinarum* exposed to different kinds of PAHs. *Journal of Environmental Sciences*, 112, 129–139.
- Zulfigarov, A., Artamonov, M., & Zulfigarov, O. (2023). Chemistry of explosives: Biodegradation of nitro-aromatic compounds. *One Health and Nutrition Problems of Ukraine*, 59, 48–61.